

CASE REPORT

Benefits of Autologous Fat Grafting Using Fat Mixed With Platelet-Rich Fibrin Matrix (PRFM) Selphyl

Richard M. Goldfarb, MD, FACS; Aaron L. Shapiro, MD

Introduction: Autologous fat grafting is important in the treatment of facial rejuvenation to treat the aging face, facial rhytids, and volume deformities. Additional uses of fat transfer include breast augmentation and buttock enhancement. Fat transfer for hand aging, as well as adding volume to body defects with fat, plays a major role in plastic and reconstructive surgery. Variability of graft survival (typically 50–70%) has lessened enthusiasm for the use of this technique. Platelet-rich fibrin matrix, however, has been shown previously to improve fat transplant survival in animal models.

Materials and Methods: This report summarizes the case of a 37-year-old woman who had fat from her outer thighs injected into her lower abdominal panus. In 2 designated sites on her lower abdomen, 8 mL of fat was injected per site (one site with fat alone and the other site a 2:1 mixture of fat to Selphyl). Eight weeks later, the patient underwent a paniclectomy (*en bloc*) resection. Specimens were then processed and evaluated for histopathology and immunohistochemistry.

Results: After removal of the *en bloc* panus, the tissue was immediately processed for histopathology. CD34 staining of regions 1 and 2 was performed. Region 1 consisted of 8 mL of fat injected into the lower abdominal panus in the subcutaneous layer. Region 2 consisted of 8 mL of fat mixed with 4 mL of Selphyl injected subcutaneously. Analysis of these regions showed viable fat in both sections; however, region 2 (8 mL of fat mixed with 4 mL of Selphyl) showed increased neovascularization.

Conclusions: The result of this case study indicates that fat mixed with Selphyl may improve graft survival by increasing both neovascularization and total cell number.

Autologous fat for use elsewhere in the body dates back to 1893 in Germany. It wasn't until the 1980s that fat was easily accessible by the development and wide use of fat after liposuction. It was, and still is, the standard of care to eliminate fat from undesirable areas of the body. Essentially, the fat transfer procedure harvests excess fat from one part of the body and then places it in another part of the body, where the additional bulk is used for cosmetic, reconstructive, and aesthetic purposes.¹

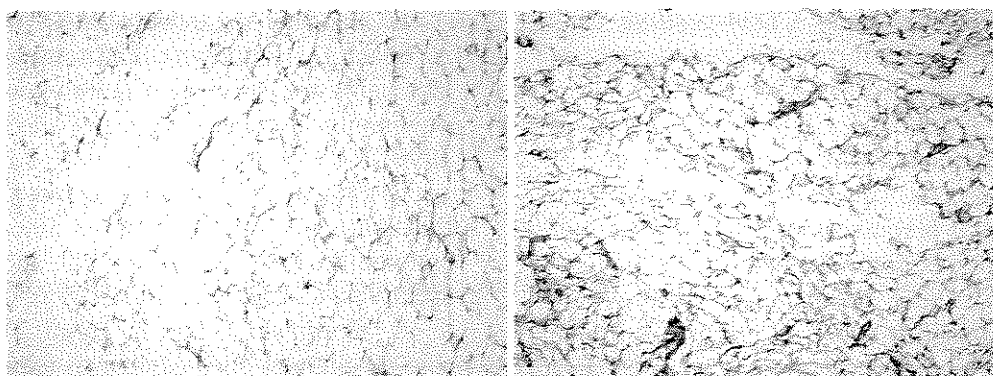
Many attempts to improve graft survival have been attempted without significant improvement.^{2,3} One method has used stem cell enhancement.^{2,3} Adipose-derived stem cells may affect graft survival in several ways.^{4–6} The stem cells may differentiate into adipocytes, endothelial cells, and vascular mural cells.⁷ Stem cells may also survive and remain as stem cells, aiding in rapid turnover or adipose tissue, which is crucial after the graft experiences ischemia and reperfusion.^{8,9} Stem cells are known to release angiogenic growth factors in response to hypoxia.^{8,9} Differentiation into endothelial cells and vascular mural cells in combination with angiogenic growth factors creates a powerful mechanism for improved graft survival through more rapid neovascularization. Platelets are also a potent source of growth factors and contain vascular endothelial growth factors, platelet-derived growth factors, and epidermal and fibroblast growth factors. These factors are crucial to stimulate endothelial budding and revascularization. Fibrin is also an essential element, not only in the presentation and release of growth factors but also in providing a matrix upon which blood vessels and fat can grow.¹⁰ If neovascularization is the key element in enhancing autologous fat graft survival, then it should be possible to influence rapid angiogenesis and hence predictability and survival of fat graft by using Selphyl to provide a clinically meaning amount of autologous platelet-rich fibrin

Received for publication August 10, 2011.

From the Center for SmartLipo, Langhorne, Pa (Dr Goldfarb) and the Department of Facial Plastic Surgery, Thomas Jefferson University Hospital, Philadelphia, Pa (Dr Shapiro).

Corresponding author: Richard M. Goldfarb, MD, FACS, Center for SmartLipo, 940 Town Center Dr, Suite F-20, Langhorne, PA 19047 (e-mail: docgstable@aol.com).

DOI: 10.5992/AJCS-D-11-00037.1



A1S. Fat Graft Alone

A2S. Fat Graft plus Selphyl®

Figure. *Semiquantitative evaluation of the CD34 staining on tissue sections prepared from fat grafts resected 8 weeks posttransplant. The graft premixed with platelet-rich fibrin matrix (A2S) shows increased cellularity and CD34 positivity over the untreated fat graft (A1S), demonstrating the benefit of using Selphyl to enhance graft viability and neovascularization.*

matrix (PRFM). This has been demonstrated in animal models.¹¹

PRFM was obtained from a patient using Selphyl (Aesthetic Factors, LLC, Wayne, NJ), a medical device cleared by the US Food and Drug Administration.¹⁰ The patient's blood is drawn into a vacuum collection tube and then centrifuged for 6 minutes at 1100 rpm. The resulting aqueous fraction, containing fibrin and platelets, is then transferred to a tube with a calcium chloride solution to initiate fibrin polymerization. Prior to complete polymerization, the solution is mixed with aspirated fat that has been prepared for lipo transfer.

Case Report

A 37-year-old woman presented to our office for a lower abdominal abdominoplasty and liposuction of her outer thighs. The patient had lost 78 lb over the past 10 months. Physical examination showed a healthy woman with a large abdominal panus. Her outer thighs showed excess adipose tissue. In August 2010, she underwent liposuction of her bilateral thighs using tumescent anesthesia. The fat was aspirated with a blunt cannula at 14 mm of mercury. A portion of the fat was decanted and processed for fat transfer. A region of her lower abdomen was preoperatively marked. Two injection sites were marked with a surgical marker and labeled A1S and A2S. Preparation was obtained by injecting 4 mL of Selphyl into premeasured 8 mL of fat.¹⁰ This PRFM was carefully injected into the fat and slowly agitated by gently stirring the fat with Selphyl. The mixture was drawn into 2-mL syringes and precisely injected by a retrograde fashion into the subcutaneous level of the premarked lower abdominal panus labeled A2S.

In October 2010, the patient underwent a lower abdominoplasty and tolerated the procedure well. After resection of her panus, the tissue was transferred to a histopathology lab for immediate processing. Harry Belin, MD, pathologist at Axis Diagnostics Lab, was blinded to the slides, and his analyses were made without knowledge of which specimens were fat alone versus fat mixed with Selphyl, and no specific scoring system was needed. Immunohistochemistry was performed on tissue sections using anti-CD34 antibody to identify engrafted progenitor cells and to indirectly assess neovascularization (Axis Diagnostics, Langhorne, Pa).

Discussion

One of the factors limiting the wider use of fat grafting in aesthetic surgery is the viability of the fat graft. As techniques for harvesting and injection evolved, results of grafting have improved. Any technique or mechanism that would enhance the graft survival would be very beneficial in cosmetic surgery. This in turn would lead to wider acceptance of this technique.^{12,13} Autologous PRFM prepared using Selphyl can stimulate neoangiogenic vascularization and fibrogenetic activity of fibroblasts to improve adipose tissue survival. Selphyl induces early development of neoangiogenic microcapillary networks, thus facilitating the delivery of proper nutrients and oxygen levels to the grafted adipose cells. An additional benefit of using Selphyl as an adjuvant to fat transplant is that the polymerization of fibrin matrix also helps to encapsulate the grafted fat, thereby stabilizing the graft and improving its chance of survival.

As illustrated in the Figure, immunohistochemical evaluation of the different fat grafts showed a marked

increase in both the number of CD34-positive cells as well as the number of forming blood vessels in the graft premixed with PRFM (A2S). It is not clear, however, whether or not the CD34+ cells represent endothelial cell precursors alone or some admixture of hematopoietic stem cells, stromal mesenchymal stem cells, and endothelial precursors. Further studies will be necessary to gain a better understanding of the temporal relationship of these events, how they interplay to promote better fat graft survival, and to determine if this initial observation has a prolonged significance. This study shows that the clinical use of Selphyl to improve fat grafting is both safe and effective in this case report and may be an important step in making fat grafting a more viable option in aesthetic surgery.^{11,14,15}

PRFM might improve graft survival, and this warrants further investigation.

References

1. Carpaneda CA, Ribeiro MT. Percentage of graft viability versus injected volume in adipose auto transplants. *Aesthetic Plast Surg.* 1994;18:17-19.
2. Zuk PA, Zhu M, Ashjian P, et al. Human adipose tissue is a source of multipotent stem cells. *Mol Biol Cell.* 2002;12:4279-4295.
3. Zuk PA, Zhu M, Mizuno H, et al. Multilineage cells from human adipose tissue: implications for cell based therapies. *Tissue Eng.* 2001;7:211-228.
4. Ersek RA, Chang P, Salisbury MA. Lipo layering of autologous fat: an improved technique with promising results. *Plast Reconstr Surg.* 1998;101:820-826.
5. Fagrell D, Enestrom S, Beggren A, Kniola B. Fat cylinder transplantation: an experimental comparative study of three different kinds of fat transplants. *Plast Reconstr Surg.* 1996;98:90-96.
6. Har-Shai Y, Lindenbaum ES, Gamliel-Lazarovich A, Beach D, Hirshowitz B. An integrated approach for increasing the survival of autologous fat grafts in the treatment of contour defects. *Plast Reconstr Surg.* 1999;104:945-954.
7. Planat-Bernard V, Silvestre JS, Cousin B, et al. Plasticity of human adipose lineage cells toward endothelial cells: physiological and therapeutic perspectives. *Circulation.* 2004;109:656-663.
8. Krupinski J, Issa R, Bujny T, et al. A putative role for platelet-derived growth factor in angiogenesis and neuroprotection after ischemic stroke in humans. *Stroke.* 1997;28:564-573.
9. Lindner V, Reidy MA. Platelet-derived growth factor ligand and receptor expression by large vessel endothelium in vivo. *Am J Pathol.* 1995;146:1488-1493.
10. Sciafani AP. Applications of platelet-rich fiber matrix in facial plastic surgery. *Facial Plast Surg.* 2009;25:270-276.
11. Oh DS, Cheon YW, Jeon YR, Lew DH. Activated platelet-rich plasma improves fat graft survival in nude mice: a pilot study. *Dermatol Surg.* 2011;37:619-625.
12. Miranville A, Heeschen C, Sengenès C, Curat CA, Busse R, Bouloumie A. Improvement of postnatal neovascularization by human adipose tissue-derived stem cells. *Circulation.* 2004;110:349-355.
13. Cervelli V, Gentile P, Scioli MG, et al. Application of platelet-rich plasma in plastic surgery: clinical and in vitro evaluation. *Tissue Eng Part C Methods.* 2009;15:625-634.
14. Sciafani AP. Platelet-rich fibrin matrix for improvement of deep nasolabial folds. *J Cosm Derm.* 2010;9:66-71.
15. Sciafani AP. Applications of platelet-rich fibrin matrix in facial plastic surgery. *Facial Plast Surg.* 2009;25:270-276.